

DCBs in the United States

The use of drug-coated balloons is creating a paradigm shift in the treatment of peripheral arterial disease by preventing restenosis and leaving nothing behind.

BY GEORGE L. ADAMS MD, MHS, AND O JESSE MENDES, BA



Restenosis is the proverbial Achilles' heel of peripheral endovascular treatment. Modalities focused on inhibiting neointimal hyperplasia, specifically drug-coated balloons (DCBs), have resulted in a paradigm shift in the treatment of peripheral arterial disease (PAD). To date, utilization of DCBs in the United States has been limited to enrollment in four ongoing clinical trials: three superficial femoral artery (SFA) trials (LEVANT 2,¹ IN.PACT SFA II,² and Lutonix SFA In-Stent Restenosis³) and one below-the-knee (BTK) trial (Lutonix BTK⁴).

Each of these trials has specific inclusion and exclusion criteria (Table 1) influencing the PAD population treated. Regarding SFA treatment, many endovascular specialists believe that a "leave nothing behind" concept is important in this vascular bed. The SFA, like no other artery

Although these drug delivery devices have shown promise, long-term data are still needed. Unlike the Zilver PTX drug-eluting stent, none of the DCBs have long-term randomized controlled trial data.

in the body, has multiple forces that influence its movement, including extension, contraction, torsion, compression, and flexion.⁵ Although modern stent designs have made stent fractures a rare occurrence, there is still a chance that these forces may compromise the integrity of a stent, leading to stent fracture and ultimately stent

TABLE 1. UNITED STATES CLINICAL TRIAL OVERVIEW

Trial Name	Target	Lesion	Rutherford Category	Outflow	Exclusion Criteria
LEVANT 2	<ul style="list-style-type: none"> Femoropopliteal artery 4–6 mm in diameter 	<ul style="list-style-type: none"> De novo or nonstented restenotic ≤ 15 cm 	2–4	One patent native outflow artery	<ul style="list-style-type: none"> Severe calcium Renal failure or CKD No adjunctive treatment modality
IN.PACT	<ul style="list-style-type: none"> SFA 4–7 mm in diameter 	<ul style="list-style-type: none"> De novo or nonstented restenotic lesions 70%–99% stenosis ≥ 4 cm and ≤ 18 cm 100% ≤ 10 cm 	2–4	Adequate outflow	<ul style="list-style-type: none"> Severe calcium CKD No adjunctive treatment modality
Lutonix ISR	<ul style="list-style-type: none"> Femoropopliteal artery 4–6 mm in diameter 	<ul style="list-style-type: none"> ≥ 50% bare-nitinol stent restenosis 4–18 cm 	2–4	One patent native outflow artery	<ul style="list-style-type: none"> Grade 4–5 stent fracture No adjunctive treatment modality
Lutonix BTK	<ul style="list-style-type: none"> Above-the-ankle tibial lesions 2–4 mm in diameter 	De novo or nonstented restenotic	4–5	NA	CKD

Abbreviations: CKD, chronic kidney disease; N/A, not applicable.

occlusion.⁵ Additionally, stents make the artery rigid, inhibiting the natural undulant flow of blood and possibly resulting in reocclusion.⁵ The DCB allows a paradigm shift in the treatment of de novo SFA stenosis by not leaving a stent behind but also in preventing restenosis.

LEVANT 2¹ and IN.PACT² focus on a specific patient population—those with predefined native SFA lesions. Patients whose lesions are > 18 cm and/or extend into the popliteal region, critical limb ischemia (Rutherford 5 and 6⁶), severely calcified vessels, and/or those with chronic kidney disease are excluded from these SFA trials.

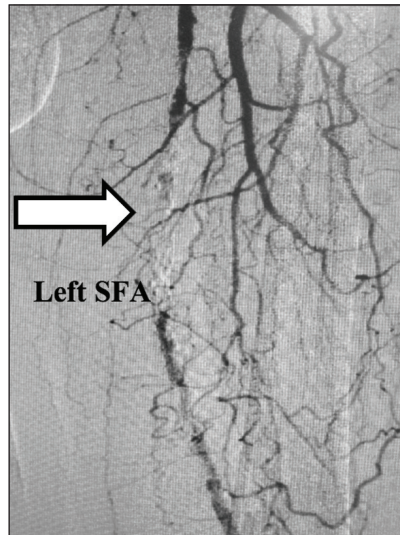


Figure 1. The left SFA preintervention.

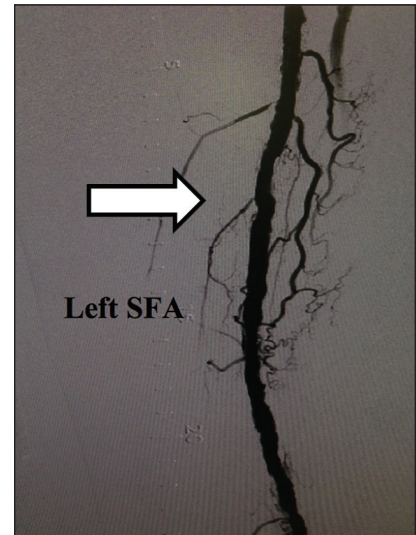


Figure 2. The left SFA postintervention with a DCB.

CASE 1

An 81-year-old man with a history of hypertension, hyperlipidemia, coronary artery disease, and diabetes was complaining of left lower extremity claudication. The ankle-brachial index of his left lower extremity was 0.54. He was found to have an occluded left SFA (Figure 1) and underwent successful percutaneous intervention with a DCB. Postintervention, his pain resolved, and 26-month duplex ultrasound confirmed that the vessel has remained patent (Figure 2).

CASE 2

A 65-year-old woman with a history of dyslipidemia, tobacco use, and PAD (left SFA stent placed 11 months earlier) presented with left lower extremity claudication. An angiogram showed in-stent reocclusion (Figure 3), and she was treated with a DCB. Currently, the vessel is widely patent at 3 months postintervention (Figure 4).

The importance of inflow patency on outflow patency is well recognized, as is the importance of outflow patency on inflow.^{9,10} Even with this knowledge, many endovascular specialists continue to avoid tibial and pedal interventions. BTK interventions are challenging because these vessels are considerably smaller (1–4 mm), heavily calcified, commonly have chronic total occlusions, and are typically located far from the access site.^{7,11} Additionally, tools and techniques for BTK interventions have historically lagged behind those for above-the-knee interventions. In the United States, tools and techniques for BTK interventions are rapidly evolving for immediate technical success.¹² However, there has been a void for devices focused on long-term vessel patency. The DCB may provide that answer.

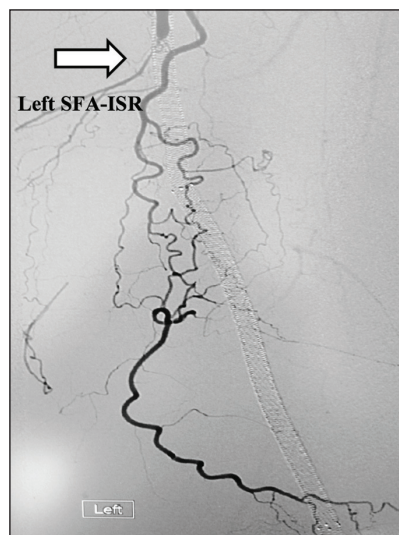

Figure 3. Preintervention image from a patient in the SFA-ISR trial.

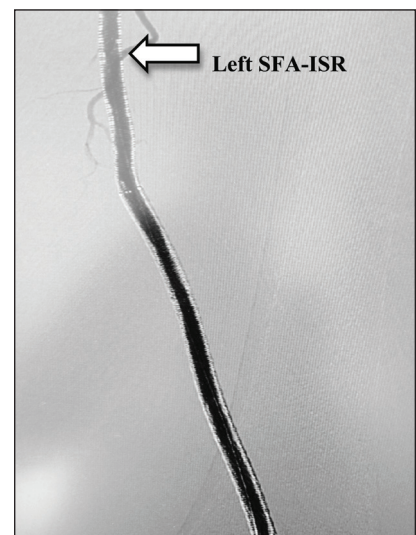


Figure 4. The 3-month postintervention imaging.

CASE 3

A 61-year-old woman with coronary artery disease, diabetes, hyperlipidemia, and hypertension presented with a nonhealing ulcer of the left great toe. She underwent endovascular intervention of the left anterior tibial artery (Figure 5) with a DCB and showed immediate technical success. She remained patent on duplex ultrasound at 8 months posttreatment. The wound healed 3 weeks postintervention (Figure 6).

Endovascular specialists in the United States are rapidly adopting drug-eluting technologies with the hope of improving long-term outcomes.¹² Devices are evolving to meet this need and currently include DCBs, drug-eluting stents, and direct drug delivery. Although these drug delivery devices have shown promise, long-term data are still needed. Unlike the Zilver PTX drug-eluting stent (Cook Medical), none of the DCBs have long-term randomized controlled trial data. Rather than being a stand-alone treatment, drug-eluting devices may be used in concert with other modalities to improve their performance. For example, with medial calcification, antineoproliferative agents may be inhibited from reaching the media and adventitia of the artery. Modification of the calcified artery by atherectomy may improve drug delivery with a DCB and improve the overall outcome.¹³ Thinking outside the box is crucial for the development of future devices and techniques to address this population in need.

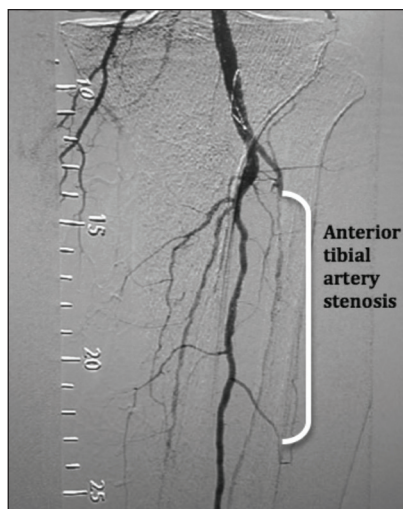


Figure 5. Preintervention imaging of the anterior tibial artery stenosis.

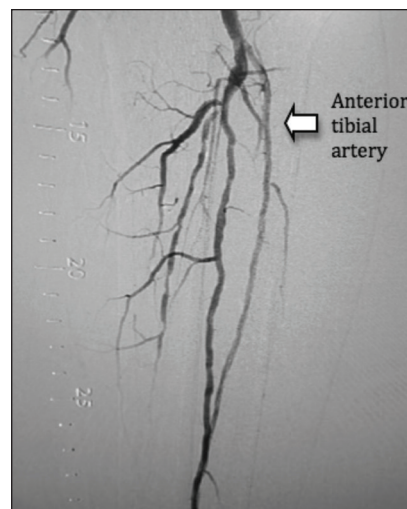


Figure 6. Postintervention result showing the patent anterior tibial artery.

CONCLUSION

As an American endovascular specialist, drug-eluting technology is changing the way we practice. The concept of leaving nothing behind by using a DCB is an ideal concept embraced by many. However, there will be times, as shown in the previously mentioned clinical trials, when either a flow-limiting dissection or recoil occurs after vessel preparation (prolonged balloon inflation or possible future use of atherectomy). Many times, this is secondary to intra-arterial or medial calcium. As a result, the best strategy would be the marriage of a scaffold and drug elution (ie, a drug-eluting stent). The Zilver PTX drug-eluting stent is currently available and utilized in the United States, with compelling randomized outcomes data in the SFA.¹⁴ Drug-eluting technologies will continue to evolve to address different patient pathologies, thus allowing for a truly personalized approach. ■

George L. Adams MD, MHS, is with Rex Health Care, University of North Carolina Health System in Raleigh, North Carolina. He is paid by Cook Medical for speaking, consulting, and physician education and is also a paid consultant for Medtronic and Bard. Dr. Adams may be reached at george.adams@rexhealth.com.

O Jesse Mendes, BA, is a graduate student in Physiology

at the University of North Carolina at Chapel Hill in North Carolina. He has disclosed that he has no financial interests related to this article.

Neither Dr. Adams nor Mr. Mendes were paid for writing this article.

1. C. R. Bard. Moxi Drug Coated Balloon vs Standard Balloon Angioplasty for the Treatment of Femoropopliteal Arteries (LEVANT 2). ClinicalTrials.gov website. <http://clinicaltrials.gov/ct2/show/record/NCT01412541>. Accessed September 2014.
2. Medtronic Endovascular. IN.PACT Admiral Drug-Eluting Balloon vs Standard Balloon Angioplasty for the Treatment of Superficial Femoral Artery (SFA) and Proximal Popliteal Artery (PPA) (IN.PACT SFA II). ClinicalTrials.gov website. <http://clinicaltrials.gov/show/NCT01566461>. Accessed September 2014.
3. C. R. Bard. Lutonix Drug Coated Balloon vs Standard Balloon Angioplasty for Treatment of Femoropopliteal In-Stent Restenosis (SFA ISR). ClinicalTrials.gov website. <http://clinicaltrials.gov/show/NCT02063672>. Accessed September 2014.
4. C. R. Bard Ltd. Lutonix DCB Versus Standard Balloon Angioplasty for Treatment of Below-The-Knee (BTK) Arteries. ClinicalTrials.gov website. <http://clinicaltrials.gov/show/NCT01870401>. Accessed September 2014.
5. Arena FJ. Arterial kink and damage in normal segments of the superficial femoral and popliteal arteries abutting nitinol stents—a common cause of late occlusion and restenosis? A single-center experience. *J Invasive Cardiol*. 2005;17:482–486.
6. Weinberg J. Arterial disease: Rutherford classification. *Vascular medicine: angiologist*. Available at <http://www.angiologist.com/arterial-disease/rutherford-classification>. Accessed September 2014.
7. Kraitzer A1, Kloog Y, Zilberman M. Approaches for prevention of restenosis. *J Biomed Mater Res B Appl Biomater*. 2008;85:583–603.
8. Gallino Mahler F, Probst P, Nachbur B. Percutaneous transluminal angioplasty of the arteries of the lower limbs: a 5 year follow-up. *Circulation*. 1984;70:619–623.
9. Davies MG, Saad WE, Peden EK, et al. Impact of runoff on superficial femoral artery endoluminal interventions for rest pain and tissue loss. *J Vasc Surg*. 2008;48:619–626.
10. Al Mahameed A. Peripheral arterial disease. Cleveland Clinic for Continuing Education website. <http://www.clevelandclinic-med.com/medicalpubs/diseasemanagement/cardiology/peripheral-arterial-disease>. Accessed September 2014.
11. El-Sayed HF. Retrograde pedal/tibial artery access for treatment of infragenicular arterial occlusive disease. *Methodist Debakey Cardiovasc J*. 2013;9:73–78.
12. Gray WA, Granada JF. Drug-coated balloons for the prevention of vascular restenosis. *Circulation*. 2010;121:2672–2680.
13. Cioppa A, Stabile E, Popusoi G, et al. Combined treatment of heavy calcified femoro-popliteal lesions using directional atherectomy and a paclitaxel coated balloon: one-year single centre clinical results. *Cardiovasc Revasc Med*. 2012;13:219–223.
14. Ansel G. The Zilver PTX randomized trial of paclitaxel-eluting stent for femoropopliteal disease: 4-year results. Presented at Vascular Interventional Advances (VIVA) 2013; October 8–11, 2013; Las Vegas, Nevada.